

# Endoscopic Resection of Peroneal Tubercle



Tun Hing Lui, M.B.B.S.(H.K.), F.R.C.S.(Edin.), F.H.K.A.M., F.H.K.C.O.S.

**Abstract:** Symptomatic hypertrophy of the peroneal tubercle can result in pain, clicking sensation, and limitation of ambulation. Surgical resection is indicated for symptomatic hypertrophied tubercle that is recalcitrant to conservative treatment. The purpose of this Technical Note is to report the details of tendoscopic resection of the hypertrophied peroneal tubercle. This is performed through zone 2 peroneus longus tendoscopy. Any associated hindfoot deformity and peroneal tendon pathology should also be addressed.

**P**eroneal tubercle is a bony projection at the lateral wall of the calcaneus. It separates the peroneus brevis tendon superiorly and the peroneus longus tendon inferiorly. The height of the peroneal tubercle of 5 mm or more is the cutoff for diagnosis of hypertrophied peroneal tubercle.<sup>1</sup> The incidence of enlarged peroneal tubercle has been reported to be from 20.5% to 24%.<sup>2,3</sup> Hypertrophied peroneal tubercle can occur in planus or cavus foot. In cavus foot, since the peroneus longus tendon is plantarflexor of the first ray, excessive force is placed on the peroneal tubercle by the peroneus longus and that can lead to hypertrophy of the peroneal tubercle.<sup>4,5</sup> Symptomatic hypertrophy of the peroneal tubercle can result in pain, clicking sensation, and limitation of ambulation.<sup>5</sup>

Tear or tenosynovitis can occur in the peroneus longus tendon and rarely the peroneus brevis tendon.<sup>6,7</sup> Surgical resection is indicated for symptomatic hypertrophied tubercle that is recalcitrant to conservative treatment. Tendoscopic resection of the hypertrophied tubercle has also been reported with the advantage of minimally invasive surgery.<sup>8,9</sup> The

purpose of this Technical Note is to report the details of tendoscopic resection of the hypertrophied peroneal tubercle. For the tendoscopy, the peroneal tendons are divided into three zones. Zone 1 tendon sheaths consist of both peroneus longus and brevis tendons from the musculotendinous junction to the peroneal tubercle. Zone 2 tendon sheaths are at the level of the peroneal tubercle. Separate tendoscopy is required for individual tendon sheath of this zone. Zone 3 tendon sheaths are at the sole and contain the peroneus longus tendon.<sup>10</sup> Zone 2 peroneus longus tendoscopy is used for endoscopic resection of the peroneal tubercle. It is indicated for symptomatic hypertrophied peroneal tubercle that is recalcitrant to conservative measures. It is contraindicated if there is severe hindfoot deformity or extensive complex tear of the peroneus longus at the region of peroneal tubercle that requires an open lateral approach. It is also contraindicated if the local bony prominence is a tumorous lesion (Table 1).

## Technique

### Preoperative Planning and Patient Positioning

Clinical examination should include any local tenderness at the tubercle and swelling and tenderness above or below the tubercle. This signifies pathology at the peroneus brevis or longus tendon. Any associated foot deformity, for example, cavus or flat foot, should be noted. Computed tomography is a useful investigation to assess the size, orientation, and morphology of the hypertrophied tubercle.

If endoscopic resection of the peroneal tubercle is the sole procedure planned, the patient can be placed in the lateral position. If foot deformity correction is also planned, the patient can be placed in the floppy lateral position. A 2.7 mm 30° arthroscope (Henke Sass Wolf, Tuttlingen, Germany) is used for this procedure. A thigh

*From the Department of Orthopaedics and Traumatology, North District Hospital, Sheung Shui, NT, Hong Kong SAR, China.*

*The author reports that he has no conflicts of interest in the authorship and publication of this article. Full ICMJE author disclosure forms are available for this article online, as [supplementary material](#).*

*Received March 28, 2017; accepted June 2, 2017.*

*Address correspondence to Tun Hing Lui, M.B.B.S.(H.K.), F.R.C.S.(Edin.), F.H.K.A.M., F.H.K.C.O.S., Department of Orthopaedics and Traumatology, North District Hospital, 9 Po Kin Road, Sheung Shui, NT, Hong Kong SAR, China. E-mail: [luithderek@yahoo.co.uk](mailto:luithderek@yahoo.co.uk)*

*© 2017 by the Arthroscopy Association of North America. Published by Elsevier. Open access under [CC BY-NC-ND license](#).*

*2212-6287/17401*

*<http://dx.doi.org/10.1016/j.eats.2017.06.006>*

**Table 1.** Indications and Contraindications of Endoscopic Resection of Peroneal Tubercle

Indications	Contraindications
Indicated for symptomatic hypertrophied peroneal tubercle that is recalcitrant to conservative measures.	Contraindicated if there is severe hindfoot deformity or extensive complex tear of the peroneus longus at the region of peroneal tubercle that requires an open lateral approach or if the local bony prominence is a tumorous lesion.

tourniquet is applied to provide a bloodless operative field. Flow inflow is by gravity, and no arthropump is used.

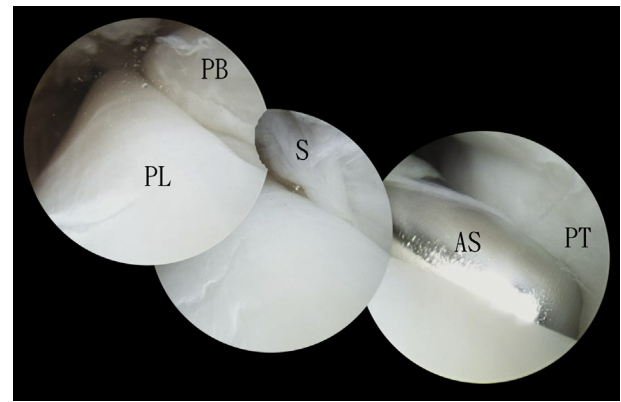
### Portal Placement

Endoscopic resection of the peroneal tubercle is performed through portals proximal and distal to the tubercle. The proximal portal is about 1 cm proximal to the proximal end of the tubercle and along the peroneal tendons. The distal portal is also 1 cm distal to the distal end of the tubercle and along the peroneal tendons (Fig 1).

### Endoscopic Resection of the Fibrous Layer Covering the Peroneal Tubercle

The distal portal is the viewing portal, and the proximal portal is the working portal. Zone 2 peroneus longus tendoscopy is performed. This is plantar to the peroneal tubercle. The peroneus longus tendon is retracted by an arthroscopic shaver (Dyonics, Smith and Nephew, Andover, MA) via the proximal portal. The fibrous layer covering the plantar surface of the peroneal tubercle is exposed. The layer is resected by the shaver to expose the bone of the tubercle (Fig 2).

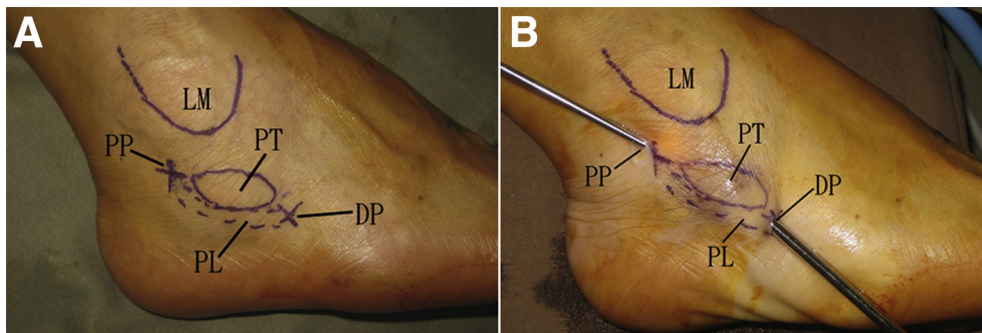
Resection of the peroneal tubercle is performed through a combination of three approaches: bone resection from the base of the tubercle toward its apex, bone resection from the distal edge of the tubercle proximally, and bone resection from the apex of the tubercle toward its base.



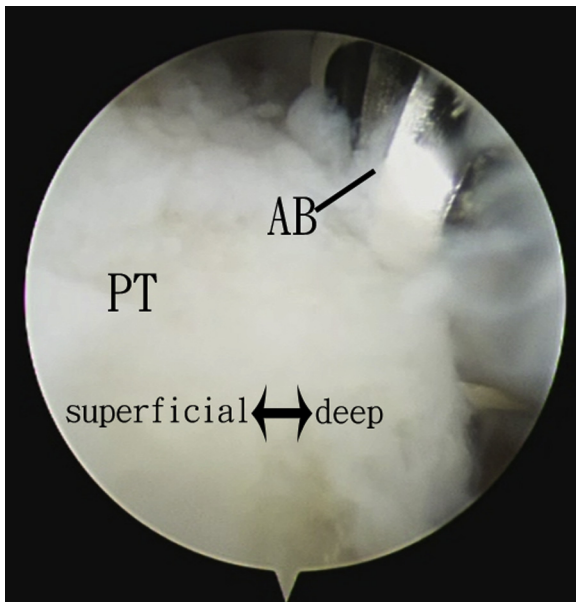
**Fig 2.** Endoscopic resection of peroneal tubercle of the right foot. The patient is in the lateral position. The distal portal is the viewing portal, and the proximal portal is the working portal. Zone 2 peroneus longus tendoscopy is performed. This is plantar to the peroneal tubercle. The peroneus longus tendon is retracted by an arthroscopic shaver via the proximal portal. The fibrous layer covering the plantar surface of the peroneal tubercle is exposed. The layer is resected by the shaver to expose the bone of the tubercle. (AS, arthroscopic shaver; PB, peroneus brevis tendon; PL, peroneus longus tendon; PT, peroneal tubercle; S, fibrous septum just proximal to the peroneal tubercle.)

### Bone Resection From the Base of the Peroneal Tubercle Toward Its Apex

The proximal portal is the viewing portal, and the distal portal is the working portal. The arthroscopic burr (Dyonics) is introduced via the distal portal. It retracts the peroneus longus tendon and sweeps toward the base of the peroneal tubercle. Resection of the peroneal tubercle starts from its base toward its apex (Fig 3). The cutting burr should face toward the tubercle, and the suction should be kept to a minimum during bone cut. This can reduce the risk of injury to the peroneus longus tendon. Starting the bone cut from the base of the peroneal tubercle can reduce the risk of formation of bone spike at its base.



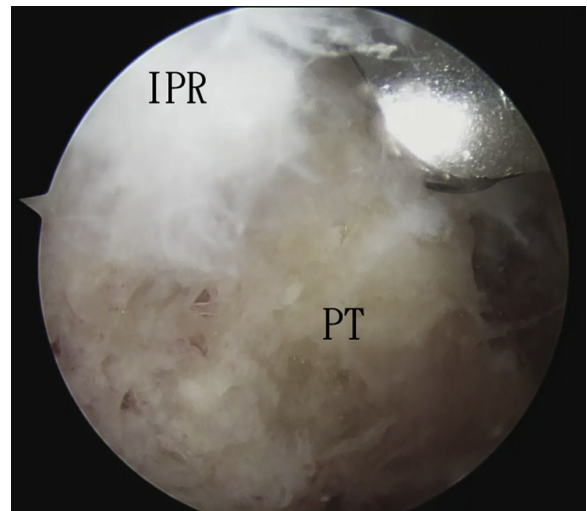
**Fig 1.** Endoscopic resection of peroneal tubercle of the right foot. The patient is in the lateral position. (A) The lateral malleolus (LM), peroneal tubercle (PT), peroneus longus tendon (PL), proximal portal, and distal portal are outlined. (B) Endoscopic resection of the PT is performed through the proximal and distal portals.



**Fig 3.** Endoscopic resection of peroneal tubercle of the right foot. The patient is in the lateral position. The proximal portal is the viewing portal, and the distal portal is the working portal. The plantar surface of the peroneal tubercle (PT) is resected from its base toward its apex by the arthroscopic burr (AB).

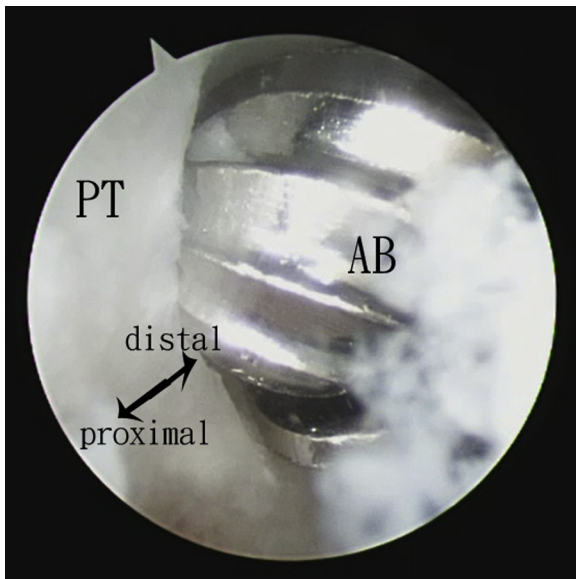
**Bone Resection From the Distal Edge of the Peroneal Tubercle Proximally**

The proximal portal is the viewing portal, and the distal portal is the working portal. The posterior edge of

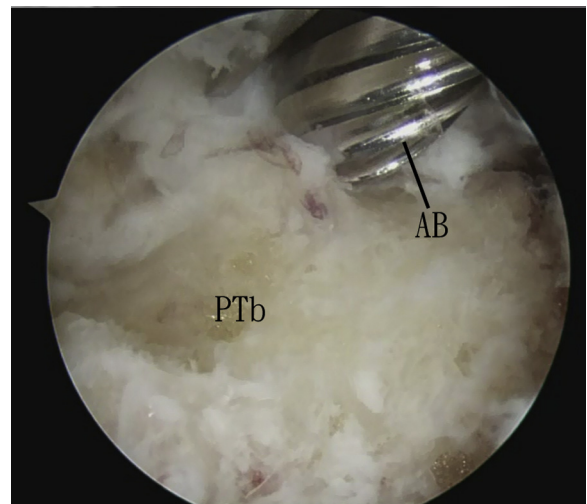


**Fig 5.** Endoscopic resection of peroneal tubercle of the right foot. The patient is in the lateral position. The proximal portal is the viewing portal, and the distal portal is the working portal. The apex of the peroneal tubercle (PT) is cut from the inferior peroneal retinaculum (IPR). The PT is then resected from its apex toward its base.

the peroneal tubercle is identified by probing with an arthroscopic probe (Acufex, Smith and Nephew). Bone resection of the peroneal tubercle can be performed by the arthroscopic burr starting at its distal edge proximally (Fig 4). It is important to avoid excessive motion of the burr in the dorsal-plantar direction in order to avoid injury to the peroneus longus and brevis tendons.



**Fig 4.** Endoscopic resection of peroneal tubercle of the right foot. The patient is in the lateral position. The proximal portal is the viewing portal, and the distal portal is the working portal. Bone resection of the peroneal tubercle (PT) can be performed by the arthroscopic burr (AB) starting at its distal edge proximally.



**Fig 6.** Endoscopic resection of peroneal tubercle of the right foot. The patient is in the lateral position. The proximal portal is the viewing portal, and the distal portal is the working portal. The bed of the peroneal tubercle (PTb) is carefully checked for any remaining bone spike. Any residual bony prominence should be resected the arthroscopic burr (AB).

**Table 2.** Pearls and Pitfalls of Endoscopic Resection of Peroneal Tubercle

Pearls	Pitfalls
The subcutaneous tissue at the portal sites is bluntly dissected to avoid injury to the sural nerve.	Careful preoperative assessment is important to differentiate a symptomatic peroneal tubercle from subtalar joint pathology.
The inferior peroneal retinaculum should not be perforated during bone resection.	Suction should be kept to a minimum during bone resection in order to avoid iatrogenic tendon injury.
The bed of the peroneal tubercle should be checked for any residual bone spike.	
Hindfoot deformity and peroneal tendon pathology should also be addressed.	

### Bone Resection From the Apex of the Peroneal Tubercle Toward Its Base

The proximal portal is the viewing portal, and the distal portal is the working portal. The apex of the peroneal tubercle is cut from the inferior peroneal retinaculum. Dissection beyond the retinaculum should be avoided in order to protect the sural nerve from injury. The peroneal tubercle is then resected from its apex toward its base (Fig 5).

### Resection of Remaining Bone Spike at the Bed of the Peroneal Tubercle

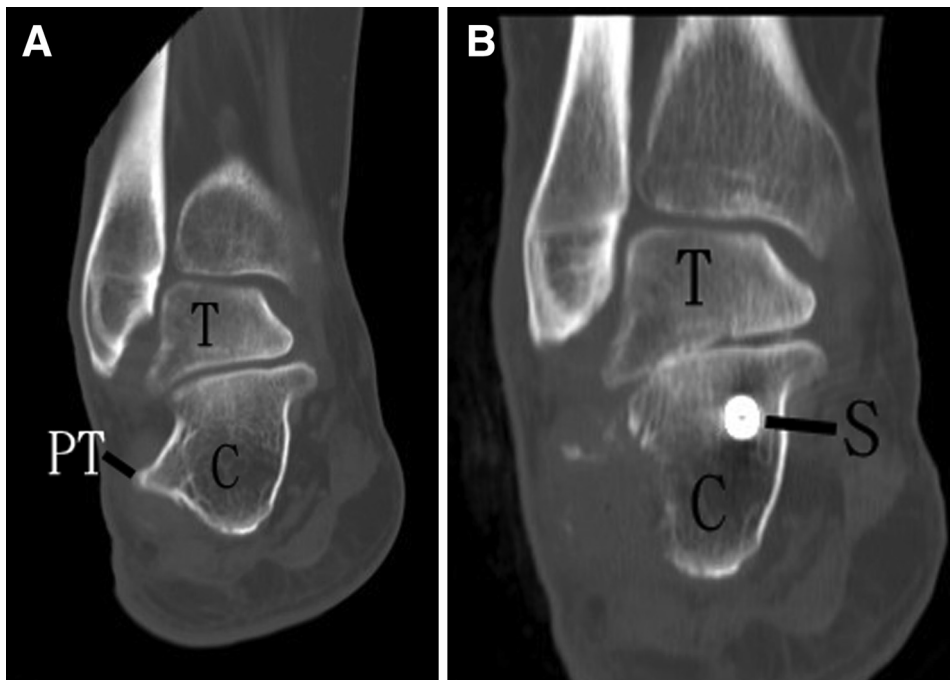
The proximal and distal portals are interchangeable as the viewing and working portals. The bed of the peroneal tubercle is then carefully checked for any remaining bone spike. Any residual bony prominence should be resected the arthroscopic burr (Fig 6, Video 1, Table 2). After complete resection of the peroneal tubercle, the peroneal tendons are examined for any tears. Endoscopic resection or repair of the tear can be performed if indicated. Any associated hindfoot

deformity can be corrected. In this illustrated case, arthroscopic subtalar arthrodesis and percutaneous first metatarsal osteotomy were performed (Fig 7).

### Discussion

Besides resection of the hypertrophied peroneal tubercle, the associated hindfoot deformity should also be corrected. The development of minimally invasive techniques of hindfoot deformity correction expands the indication of tendoscopic resection of the peroneal tubercle.<sup>11-13</sup> This is not a technically demanding approach and can be handled by the average foot and ankle arthroscopist. However, in order to have good clinical results, the surgeon should follow the technical steps strictly in order to ensure complete resection of the tubercle and avoid complications.

The advantages of this minimally invasive approach include better cosmesis, less soft-tissue dissection, low risk of wound complication, and less chance of injury to the sural nerve. The potential risks of this procedure



**Fig 7.** Endoscopic resection of peroneal tubercle of the right foot. The patient is in the lateral position. (A) preoperative computed tomography shows the hypertrophied peroneal tubercle. (B) postoperative computed tomography shows that the peroneal tubercle is resected. (C, calcaneus; S, screw transfixing the subtalar joint as arthroscopic subtalar arthrodesis is performed in the illustrated case; T, talus.)

**Table 3.** Advantages and Risks of Endoscopic Resection of Peroneal Tubercle

Advantages	Risks
Less wound complication	Incomplete resection of the tubercle
Less soft tissue trauma	with residual bone spike impinging
Better cosmesis	on the peroneal tendons
Less chance of injury to the sural nerve	Sural nerve injury
	Peroneal tendon injury

include incomplete resection of the tubercle with residual bone spike impinging on the peroneal tendons, sural nerve injury, and peroneal tendon injury (Table 3).

### References

- Zanetti M. Founder's lecture of the ISS 2006: borderlands of normal and early pathological findings in MRI of the foot and ankle. *Skeletal Radiol* 2008;37:875-884.
- Laidlaw PP. The varieties of the os calcis. *J Anat Physiol* 1904;38:133-143.
- Edwards ME. The relations of the peroneal tendons to the fibula, calcaneus, and cuboidenum. *Am J Anat* 1928;42: 213-242.
- Ruiz JR, Christman RA, Hillstrom HJ. Anatomical considerations of the peroneal tubercle. *J Am Podiatr Med Assoc* 1993;83:563-575.
- Bisceglia G, Sirota A, Dull D. An unusual case of hypertrophied peroneal tubercles. *J Am Podiatr Assoc* 1983;9: 481-482.
- Boya H, Pinar H. Stenosing tenosynovitis of the peroneus brevis tendon associated with hypertrophy of the peroneal tubercle. *J Foot Ankle Surg* 2010;49:188-190.
- Ochoa LM, Banerjee R. Recurrent hypertrophic peroneal tubercle associated with peroneus brevis tendon tear. *J Foot Ankle Surg* 2007;46:403-408.
- Van Dijk CN, Kort N. Tendoscopy of the peroneal tendons. *Arthroscopy* 1998;14:471-478.
- Lui TH. Endoscopic resection of the peroneal tubercle. *J Foot Ankle Surg* 2012;51:813-815.
- Lui TH, Mak CY. Peroneus longus tendoscopy at the sole: a cadaveric study. *Arthroscopy* 2015;31:1338-1342.
- Lui TH. Percutaneous posterior calcaneal osteotomy. *J Foot Ankle Surg* 2015;54:1188-1192.
- Lui TH. Percutaneous dorsal closing wedge osteotomy of the metatarsal neck in management of metatarsalgia. *Foot* 2014;24:180-185.
- Lui TH. Percutaneous sagittal plane closing wedge osteotomy of the first metatarsal. *Eur J Orthop Surg Traumatol* 2014;24:243-246.