



Posterior Capsulotomy of the Knee: Treatment of Minimal Knee Extension Deficit

João Luiz Ellera Gomes, Ph.D., Murilo Anderson Leie, M.D., Arthur de Freitas Soares, M.D., Márcio Balbinotti Ferrari, M.D., and George Sánchez, B.S.

Abstract: The loss of knee extension, even if minimal, is disabling and considerably affects the individual's quality of life. This loss of extension can be a consequence of prior surgery, including a previous anterior cruciate ligament reconstruction. Although this loss of extension may be treated through an isolated arthroscopic procedure, a more severe case may warrant an invasive approach. In these cases, a posterior capsulotomy of the knee may be done if all conservative measures have been exhausted. This procedure has been proven to be safe and effective in the re-establishment of full extension in the setting of a minor flexion contracture of the knee. The purpose of this Technical Note was to describe our preferred technique when performing an open posterior capsulotomy of the knee for the treatment of minimal extension deficit.

The lack of knee extension is challenging to treat because of the variety of complaints and overall decrease in the quality of life associated with this pathology. The etiology resulting in the lack of knee extension may be acute, such as involvement in a motor vehicle accident, or chronic, such as repetitive microtrauma due to participation in sport activities. Moreover, it may be a consequence of a prior surgical procedure.^{1,2} Regardless the cause, the consequences and overall injury pattern associated with lack of knee extension are generally similar: quadriceps weakness unresponsive to exercises, anterior knee pain, and a progressive inability to practice physical activities.³ As a result of the inability to appropriately extend the knee, many patients begin to feel anterior knee pain

even for activities of daily living, including walking on a flat surface or climbing stairs.⁴ In the setting of a major traumatic event or prior surgical treatment, development of arthrofibrosis may occur and result in limitation in range of motion with initial treatment centered on arthroscopic release of the anterior adhesions of the knee.^{5,6} However, this procedure may not fully restore the range of motion; therefore, a more invasive procedure capable of a full release and correction of the deficit may be necessary.⁷ For such cases, an open posterior capsulotomy is a reasonable treatment option. An open posterior capsulotomy may also be undertaken in cases of knee extension deficit secondary to multiple lesser trauma events as a result of regular participation in sports. Nevertheless, this procedure is not recommended for those with tibiofemoral osteoarthrosis or for whom other, less invasive treatment options have not been tried. Indications and contraindications are summarized in [Table 1](#).

However, this procedure is not free of potential complications given the close proximity of several neurovascular structures. Furthermore, there remains a lack of long-term follow-up studies reporting on outcomes following this procedure. Moreover, genu recurvatum resulting from an excessive posterior release to correct the extension deficit is also, at least theoretically, a potential adverse effect of a posterior capsulotomy. The purpose of this Technical Note is to describe our preferred technique when performing an open posterior capsulotomy of the knee for the treatment of minimal extension deficit.

From the Hospital de Clínicas de Porto Alegre (J.L.E.G., M.A.L., A.d.F.S., M.B.F.), Porto Alegre, Rio Grande do Sul, Brazil; and Steadman Philippon Research Institute (G.S.), Vail, Colorado, U.S.A.

The investigation was performed at the Hospital de Clínicas de Porto Alegre, Brazil.

The authors report that they have no conflicts of interest in the authorship and publication of this article. Full ICMJE author disclosure forms are available for this article online, as [supplementary material](#).

Received March 8, 2017; accepted June 6, 2017.

Address correspondence to João Luiz Ellera Gomes, Ph.D., 81, Desembargador Esperidião de Lima Medeiros Street, Três Figueiras, Porto Alegre, RS, Brazil. E-mail: elleragomes@gmail.com

© 2017 by the Arthroscopy Association of North America. Published by Elsevier. Open access under [CC BY-NC-ND license](#).

2212-6287/17313

<http://dx.doi.org/10.1016/j.eats.2017.06.033>

Table 1. Indications and Contraindications of the Technique

Indications	Contraindications
Contracture of the knee of 10° or more	Tibiofemoral osteoarthritis
Failure of other treatment options less invasive	Gastrocnemius muscular shortening

Surgical Technique

Patient Positioning

The patient is placed supine on the surgical table (Video 1). Following induction of general anesthesia, a thigh tourniquet is placed on the proximal aspect of the operative limb. Both knees are then prepared and draped in a sterile fashion. Before starting the procedure, the following examination under anesthesia is performed to assess the degree of extension deficit: first, the knees are placed at the same level and then the distance between the heel and the surgical table is noted for each limb. The affected knee with the extension deficit will demonstrate a shorter distance between the heel and surgical table than the contralateral limb. To confirm these findings, the heels are placed at the same level. If the knee with the extension deficit is at a greater height than the contralateral, nonsymptomatic knee, then this provides further evidence of flexion contracture of the knee (Fig 1). We believe that this physical examination is reliable and reproducible and, ultimately, allows for a thorough comparison between the affected and contralateral limb. Moreover, this technique is easily performed directly prior to surgery and provides confirmation of the diagnosis before proceeding with the surgical treatment. However, if an extension deficit is suspected in both knees, then this physical examination is not applicable. Following the physical examination, the

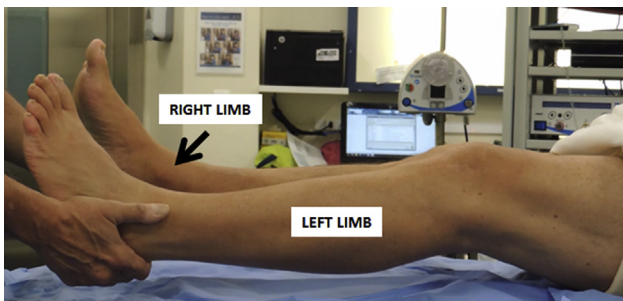


Fig 1. To evaluate the loss of knee extension, we perform a physical examination following general anesthesia. As the patient lies supine on the surgical table, the knees are placed at the same level and then the distance between the heel and surgical table is noted for each limb. The affected knee with the extension deficit will demonstrate a shorter distance between the heel and surgical table than the contralateral limb. In this figure, the extension deficit is seen in the left knee.

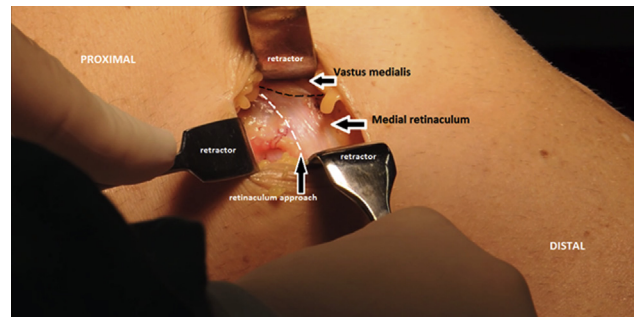


Fig 2. Following the initial incision in the affected left knee, the medial retinaculum and vastus medialis (black dots). An incision is performed obliquely from proximal to distal (white dots), and then the posteromedial capsule of the knee can be accessed and evaluated.

surgical limb is exsanguinated. Afterward, the tourniquet is inflated to 250 to 350 mmHg.

Skin Incision and Approach

The medial femoral epicondyle is identified, and then a 4-cm incision is performed from the posterior edge of the medial epicondyle and extended posteriorly to the medial femoral condyle. The subcutaneous tissue is then carefully dissected, taking care to avoid the infrapatellar branch of saphenous nerve and vein. Following the initial incision, an oblique incision is performed across the medial retinaculum (Fig 2). Following this, the thin and translucent layer of the posteromedial synovial recess is visualized.

Posterior Capsulotomy of the Knee

A 2-cm incision is then performed on the posteromedial capsule with an electrocautery to arrive at a full exposure of the posterior compartment. At this point, we suggest careful palpation to identify key posterior knee structures and landmarks including the posterior cruciate ligament, posterior borders of the femoral condyle, and posterior capsule. Careful

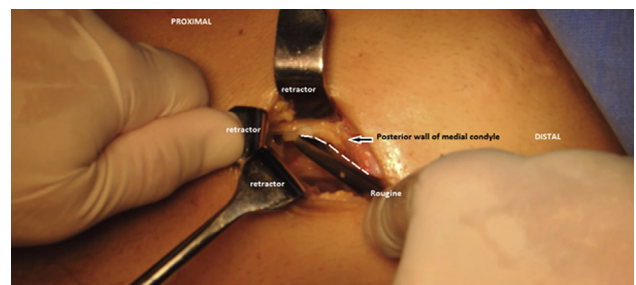


Fig 3. Once the capsule is accessed in the left knee, a rougine is used to detach the posterior capsule insertion on the medial and lateral femoral condyles. The release must be completed and performed from medial to lateral. Of note, care must be taken to avoid damage to the meniscus or neurovascular bundle.

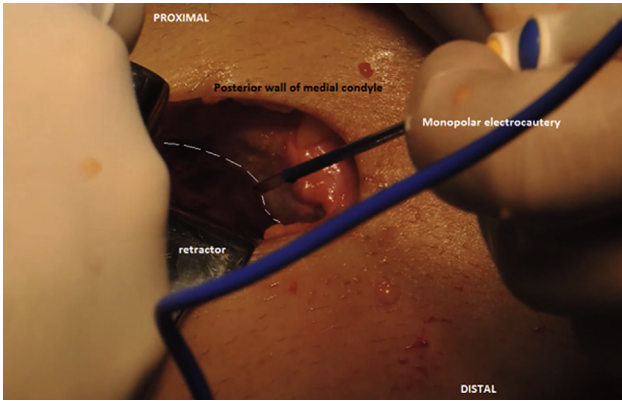


Fig 4. A monopolar electrocautery device is used to remove scar tissue and any remaining capsular thickening following the use of the rougine on the left knee. Care must be taken to not harm the neurovascular bundle or posterior cruciate ligament attached on the tibial plateau.

palpation is absolutely imperative given the small incision that does not allow for full visualization of all structures and landmarks. The release of the capsule is then progressively performed from medial to lateral through use of a combination of electrocautery and curved osteotomes, which are progressively moved from distal to proximal to arrive at a full release of the femoral attachment of the capsule (Fig 3). In our procedure, the tibial capsule attachment, unlike the femoral attachment, is preserved. The complete release of the posterior capsule must be achieved with care taken to avoid potential damage to the neighboring neurovascular structures. In some cases, a release of the medial gastrocnemius head may also be done in addition to the release of the capsule.

Checking and Confirming the Release

The posterior compartment of the knee is then thoroughly palpated once more to verify if any residual capsular attachments remain. At this point, any

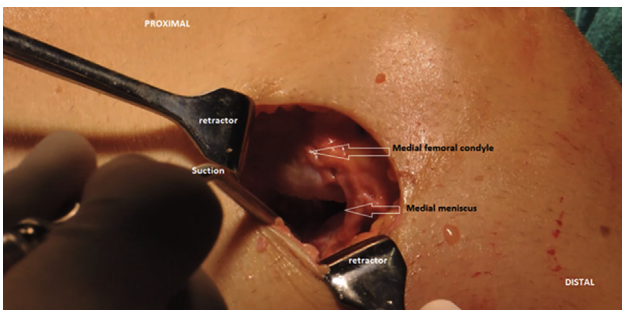


Fig 5. Once the capsulotomy is fully performed, the medial femoral condyle and posterior horn of the medial meniscus of the left knee can be easily visualized. During this step, palpation of the lateral structures is absolutely necessary to evaluate the capsular release. In some cases, a lateral incision must be done to achieve a complete resection.

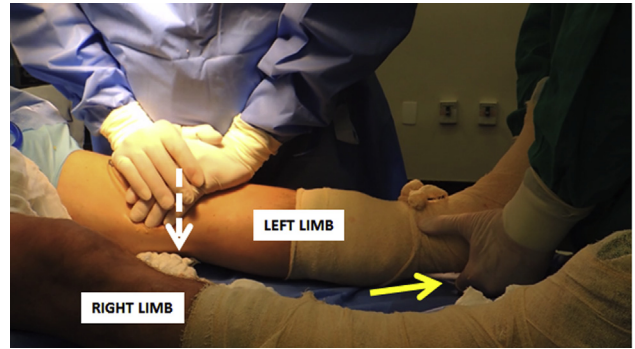


Fig 6. If any extension deficit remains in the left knee, a careful manipulation may be performed by applying an anterior to posterior force on the knee to fully resolve the flexion contracture. The assistant slightly raises the affected limb from the table (yellow arrow), and then the surgeon applies a series of 5 to 10 pushes on the knee from anterior to posterior, thereby forcing further extension until knee extension is equal for each limb.

remaining capsular attachments are released to arrive at a full and thorough capsulotomy. Afterward, scar tissue formation and adhesions are released through use of a monopolar electrocautery device (Fig 4). As the final step of verification, the posterior femoral condyle and medial meniscus are visualized and palpated to confirm a thorough release (Fig 5). Then, the correction of the extension deficit is examined through physical examination as previously described. First, the knees are placed at the same level. If the distance between the heel and surgical table is not equal for the limbs, then this provides evidence of an incomplete release. For further confirmation if an incomplete release is suspected, the heels are placed at the same level. Once the heels are placed at the same level, then the knees, both affected and contralateral, should demonstrate unequal distances to the surgical table. Ultimately, if unequal distances are noted in each of these portions of the physical examination, then this demonstrates evidence of flexion contracture that

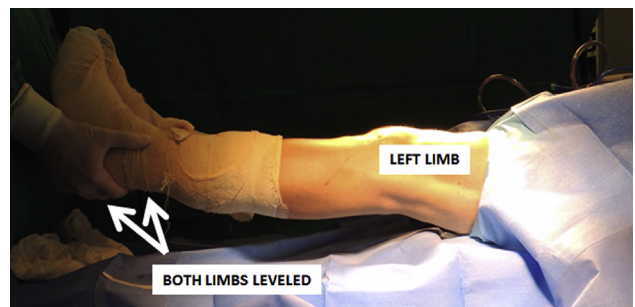


Fig 7. The final result of our technique is checked using the same physical examination as done prior to surgery. At this time, both heels must be at the same distance from the surgical table when each knee is leveled. This confirms the resolved deficit in knee extension of the left knee.

Table 2. Advantages and Limitations of the Technique

Advantages	Limitations
Direct visualization of posterior structures of the knee	Risk of damaging the neurovascular bundle and PCL
Direct palpation of scars and capsule thickening	Hematoma in the posteromedial compartment of the knee
Complete release of the posterior capsule	Minimal risk of progressive posterior knee laxity and genu recurvatum
Small skin incision	

PCL, posterior cruciate ligament.

requires further release. If further release is needed, then careful manipulation may be performed by applying an anterior to posterior force on the affected knee to fully resolve the flexion contracture (Fig 6). In some cases, a posterolateral incision may be needed to release the lateral aspect of the posterior capsule when the posteromedial approach is insufficient. Following the manipulation and prior to closure, the extension deficit is inspected once more. Once a full restoration of knee extension is confirmed, the wound is closed (Fig 7).

Wound Closure

The wound is copiously irrigated with saline solution. Following this, a combination of ropivacaine 7.5 mg/mL (20 mL) and epinephrine (2 mL) are injected in the subcutaneous layer over the medial incision to maximize hemostasis. Afterward, the tourniquet is released and a coagulator is used for hemostasis. The capsule must remain open as the retinaculum and subcutaneous layer are closed with no. 1.0 Vicryl suture (Ethicon, Somerville, NJ) and no. 2.0 Vicryl suture (Ethicon), respectively. The skin layer is then closed through use of no. 4.0 Mononylon suture (Ethicon). The advantages and disadvantages and pearls and pitfalls associated with the described procedure are listed in Tables 2 and 3, respectively.

Postoperative Rehabilitation

Following the procedure, the affected limb is kept in a brace in extension for 7 days. Nonsteroidal anti-inflammatory drugs are prescribed and taken to control the physiological response to surgical trauma. Physical therapy is then initiated once the brace is removed at 7 days following surgery. The ultimate goal of the rehabilitation program is to maintain the knee extension that was achieved as a result of the procedure. Moreover, most patients with chronic loss of knee extension also demonstrate atrophy of the quadriceps muscle, which is addressed through physical therapy.

Discussion

The inability to fully extend the knee joint as a result of a traumatic event or prior surgery may be tolerable to sedentary and minimally active patients. However, this becomes a limiting issue for those involved in sports

and leading active lifestyles in a very short period of time.³ Traditional surgery performed to treat patellofemoral disorders has been proven to be ineffective if the issue is due to excessive pressure over the cartilage imposed by the lack of full extension. Although the cartilage of the patellofemoral joint is one of the thickest and most durable in the body, prolonged flexion contracture of the knee results in a force overload on the joint with an accompanying increase in subchondral intraosseous pressure⁸ due to the increase in force seen with an increasing flexion angle of the knee.⁹ Therefore, a lateral retinaculum release, Maquet Procedure¹⁰ or Fulkerson osteotomy¹¹ may be effective in the treatment of malalignment of the knee. However, these procedures cannot resolve flexion contracture of the knee, which compromises extension of the knee and results in force overload on the patellofemoral joint. Therefore, a posterior capsulotomy may be performed to resolve the deficit in knee extension. Because of the potential risks associated with this procedure including progression to genu recurvatum, this procedure is not performed on a widespread basis. However, in our clinical experience, we have not seen a high complication rate associated with this procedure. With care and a thorough knowledge of the anatomy and neighboring structures, this procedure is reliable, reproducible, and safe. Moreover, a posterior capsulotomy allows for a full return to sport without incidence of recurrence. In our previous patients treated through a posterior capsulotomy, no patients have reported a full return of flexion contracture. Although some patients have undergone additional surgery, any further surgery was done to treat tibiofemoral cartilage degeneration. However, the patients remained satisfied with their initial results from the posterior capsulotomy.

Lobenhoffer et al.¹² reported extension recovery in 24 patients with flexion contracture who underwent

Table 3. Pearls and Pitfalls of the Technique

Pearls	Pitfalls
Careful tissue dissection is paramount to avoid damage to the neurovascular bundle	Inaccurate identification of structures and landmarks
Complete the detachment of the femoral capsule from medial to lateral	Damage of the neurovascular bundle, PCL, and posterior horn of the meniscus may occur during capsular release, if performed inadequately
Search for any scar tissue formation or residual capsular attachments by direct palpation	Incomplete release of the posterior capsule may result in surgical failure
Leave the tibial insertion of the knee capsule intact	
Leave the capsule open while performing wound closure	
Careful manipulation of the limb is necessary to release any residual capsular attachment points	

posterior capsule release of the knee. Postoperatively, Lysholm scores ranged from 62 to 88 whereas the knee contracture angle ranged from 17 to 2 degrees. Another recent study has also reported that open posterior capsulotomy effectively treated 12 patients with lack of full extension after anterior cruciate ligament reconstruction. In their cohort, 93% restored the complete extension after an average follow-up time of 38 months, with one complaint of knee instability at 6 months following the procedure.¹³ Some authors have suggested that arthroscopic release by a posteromedial approach may be useful to release the capsule in less severe cases.^{14,15} In conclusion, an open posterior capsulotomy is a worthwhile procedure capable of effectively treating minimal extension deficit of the knee.

References

1. DeHaven K, Cosgarea A, Sebastianelli W. Arthrofibrosis of the knee following ligament surgery. *Instr Course Lect* 2013;52:369-381.
2. Petsche TS, Hutchinson MR. Loss of extension after reconstruction of the anterior cruciate ligament. *J Am Acad Orthop Surg* 1999;7:119-127.
3. Austin JC, Phornphutkul C, Wojtys EM. Loss of knee extension after anterior cruciate ligament reconstruction: effects of knee position and graft tensioning. *J Bone Joint Surg Am* 2007;89:1565-1574.
4. Dye SF. The pathophysiology of patellofemoral pain: A tissue homeostasis perspective. *Clin Orthop Relat Res* 2005;436:100-110.
5. Cosgarea AJ, DeHaven KE, Lovelock JE. The surgical treatment of arthrofibrosis of the knee. *Am J Sports Med* 1994;22:184-191.
6. Mayr HO, Stöhr A. Arthroscopic treatment of arthrofibrosis after ACL reconstruction. Local and generalized arthrofibrosis. *Oper Orthop Traumatol* 2014;26:7-18 [in German].
7. Gomes JLE, Marczyk LR, Ruthner RP. Arthroscopic protocol for treatment of knee extension block after patellar ACL reconstruction. *J Knee Surg* 2002;15:35-38.
8. Sanchis-Alfonso V. *Anterior knee pain and patellar instability*. London: Springer-Verlag, 2006;57-61.
9. Heegaard J, Leyvraz PF, Curnier A, Rakotomanana L, Huiskes R. The biomechanics of the human patella during passive knee flexion. *J Biomech* 1995;28:1265-1279.
10. Maquet P. Advancement of the tibial tuberosity. *Clin Orthop Relat Res* 1976;115:225-230.
11. Fulkerson JP. Anteromedialization of the tibial tuberosity for patellofemoral malalignment. *Clin Orthop Relat Res* 1983;177:176-181.
12. Lobenhoffer HP, Bosch U, Gerich TG. Role of posterior capsulotomy for the treatment of extension deficits of the knee. *Knee Surg Sports Traumatol Arthrosc* 1996;4:237-241.
13. Tardy N, Thaunat M, Sonnery-Cottet B, Murphy C, Chambat P, Fayard JM. Extension deficit after ACL reconstruction: Is open posterior release a safe and efficient procedure? *Knee* 2016;23:465-471.
14. LaPrade RF, Pedtke AC, Roethle ST. Arthroscopic posteromedial capsular release for knee flexion contractures. *Knee Surg Sports Traumatol Arthrosc* 2008;16:469-475.
15. Tröger M, Holschen M. Arthroscopic arthrolysis for the treatment of movement disorders of the knee. *Oper Orthop Traumatol* 2014;26:361-368.