

Consolidated Proximal Biceps Tenodesis and Subscapularis Repair



Kyle E. Fleck, M.D., and Larry D. Field, M.D.

Abstract: Pathologic changes to the biceps tendon including subluxation are frequently encountered in patients with subscapularis tears. Operatively managing these combined lesions can be difficult depending on the status of the subscapularis tendon and the degree of biceps medialization. The presented technique is an effective and relatively simple method that simultaneously and efficiently provides for secure tenodesis of the biceps and fixation of subscapularis tendon detachment.

Anterior shoulder pathology is a commonly encountered problem for the shoulder surgeon and can be difficult to accurately discern on clinical examination. Both biceps tendon pathology and subscapularis pathology can cause significant symptoms, and often, these 2 entities occur concurrently. Previous studies have shown that clinical examination alone often unreliably detects proximal biceps tendon pathology.¹⁻³ Likewise, upper-border subscapularis tears are often found in conjunction with proximal biceps tendon injury and subluxation, thereby further complicating clinical assessment.⁴

Clinical assessment of the shoulder begins with a thorough examination and 3-view radiographic series of the shoulder, including anteroposterior, axillary, and scapular Y views. Clinical assessment often shows anterior shoulder pain both at rest and associated with activities. Patients will often have tenderness to palpation along the bicipital groove and subscapularis tendon insertion. The proximity of these 2 structures makes it difficult to isolate the pathology using palpation alone. Specific examinations can

help identify symptoms due to pathology related to both the long head of the biceps and the subscapularis tendon, and these physical examination tests can also aid in differentiating between these 2 pathologic conditions. Bicipital pathology examinations around the shoulder include the Speed and Yergason tests, whereas the lift-off and belly-press tests are common tests when evaluating for subscapularis tendon pathology. Even with specific examination tests, however, it can be difficult to determine whether these problems occur in isolation or are both present in a specific patient. Magnetic resonance imaging without contrast can further be used as an adjunct to the clinical examination to help discern the cause of anterior shoulder pain and help plan for operative intervention when nonoperative management has failed.

Treatment of proximal biceps pathology often begins with nonoperative management including physical therapy, nonsteroidal anti-inflammatory medications, activity modification, and corticosteroid injections.⁵ If nonoperative management fails to adequately reduce the patient's symptoms, surgical management commonly involves either biceps tenodesis or tenotomy.⁶ Some researchers have reported a significant incidence of complications after tenotomy, including the relatively common occurrence of the so-called Popeye deformity, biceps cramping, and biceps fatigue.⁷ When biceps tenodesis is used as the surgical treatment instead of tenotomy, one must decide on the location of the tenodesis. Moreover, although there is controversy regarding a preferential location for biceps tenodesis, Green et al.⁸ recently reported identifying no significant differences regarding outcomes when comparing a suprapectoral versus subpectoral location site for tenodesis.

Symptomatic subscapularis tendon tears, whether partial or complete, are often treated surgically given

From the Mississippi Sports Medicine and Orthopaedic Center, Jackson, Mississippi, U.S.A.

The authors report the following potential conflict of interest or source of funding: L.D.F. receives support from AANA. Full ICMJE author disclosure forms are available for this article online, as [supplementary material](#).

Received February 9, 2017; accepted July 14, 2017.

Address correspondence to Kyle E. Fleck, M.D., Mississippi Sports Medicine and Orthopaedic Center, 1325 Fortification St, Jackson, MS 39202, U.S.A. E-mail: Kfleck1212@gmail.com

© 2017 by the Arthroscopy Association of North America. Published by Elsevier. Open access under [CC BY-NC-ND license](#).

2212-6287/17165

<http://dx.doi.org/10.1016/j.eats.2017.07.020>

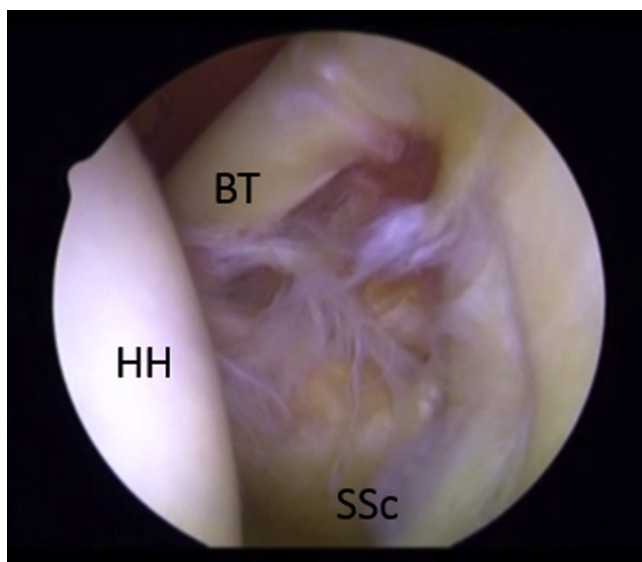


Fig 1. Arthroscopic view of the left shoulder, with the patient in the beach-chair position and the 30° arthroscope in the posterior viewing portal. (BT, biceps tendon; HH, humeral head; SSc, subscapularis tendon.)

the biomechanical importance of the subscapularis tendon to shoulder mechanics and function and because of the persistent symptoms that these lesions commonly produce.⁹⁻¹⁴ However, arthroscopic repair of subscapularis tendon tears can be technically challenging, especially when associated with a concurrent pathology of the proximal biceps tendon.

A surgical technique that addresses both the biceps tendon pathology and the often-associated subscapularis tear is presented in this article. We believe that this technique provides a simple and effective method for accomplishing both arthroscopic supra-pectoral biceps tenodesis and subscapularis repair.

Surgical Technique

Diagnostic Arthroscopy and Portal Placement

The patient is first carefully evaluated under anesthesia in the supine position for the assessment of range of motion and glenohumeral stability and then prepared and draped in sterile fashion in the beach-chair position (our preferred position for rotator cuff surgery). A diagnostic shoulder arthroscopy is completed using both the standard anterior and posterior glenohumeral joint portals. A 30° arthroscope is placed into the standard posterior portal, as is our preference, but a 70° arthroscope is occasionally used when necessary to improve viewing of the anterior structures. While the rotator interval is being visualized through the posterior portal (Fig 1), a spinal needle is used to localize the best position for the anterior portal at the central portion of the rotator interval capsule. A 7-mm arthroscopic trocar and cannula (Smith & Nephew, Andover, MA) are then

inserted anteriorly. After anterior and posterior portal placement, a careful and thorough glenohumeral joint assessment is completed. When a significant partial-thickness or complete subscapularis tendon tear is identified and a repair is planned, the biceps is likewise carefully evaluated for fraying and/or subluxation out of the bicipital groove (Fig 2). Having established an anterior portal previously, the surgeon can perform evaluation of the biceps tendon and its mobility using an arthroscopic instrument, as shown in Figure 3. Often, subscapularis pathology and biceps subluxation are identified concurrently, and incorporation of the biceps into the subscapularis repair may be possible. After a subscapularis tear is noted that will require repair, arthroscopic excision of the central portion of the rotator interval capsule is carried out by use of a standard soft-tissue arthroscopic shaver blade to create a rotator interval “window” (Fig 4) through which the extra-articular, anterior surface of the subscapularis tendon may be visualized. This rotator interval window is very valuable not only because it greatly improves visualization of the subscapularis tendon but also because it facilitates suture passage and knot tying on the anterior surface of the subscapularis.

Once the subscapularis tendon tear is identified, debridement of this tear along with light abrasion of the lesser tuberosity is carried out in preparation for suture anchor placement. The biceps tendon can be effectively incorporated into the subscapularis repair, and on occasion, when the biceps tendon subluxates medially, it may actually be identified within the substance of the

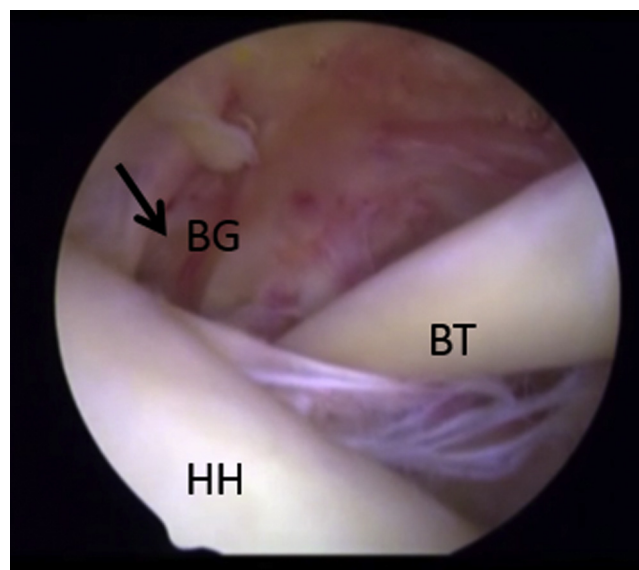


Fig 2. Arthroscopic view of the left shoulder, with the patient in the beach-chair position and the 30° arthroscope in the posterior viewing portal, showing the evaluation of the biceps tendon (BT) position. The BT can be seen subluxated medially out of the bicipital groove (BG; arrow). (HH, humeral head.)

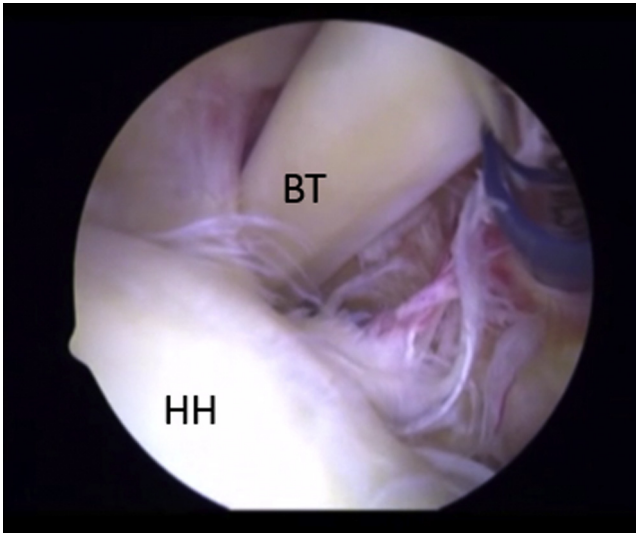


Fig 3. Arthroscopic view of the left shoulder, with the patient in the beach-chair position and the 30° arthroscope in the posterior viewing portal, showing that, with the use of an instrument, the biceps tendon (BT) can be manipulated and easily moved in and out of the bicipital groove. The BT is being replaced back into the bicipital groove with the use of a shaver. (HH, humeral head.)

subscapularis tendon itself as the biceps tendon progressively medializes within a split in the subscapularis tendon (as shown in Fig 4 and Video 1). The biceps

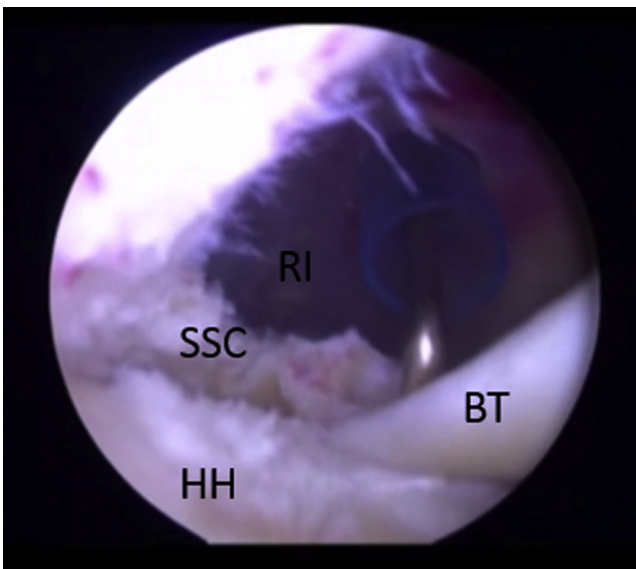


Fig 4. Arthroscopic view of the left shoulder, with the patient in the beach-chair position and the 30° arthroscope in the posterior viewing portal, after arthroscopic debridement and creation of the rotator interval window (RI). After debridement of the rotator interval, subscapularis, and lesser tuberosity, better visualization of the subluxated biceps tendon (BT) can be achieved. As is clearly shown, the BT is subluxated along the lesser tuberosity and into the subscapularis tendon (SSC) upper-border tear. (HH, humeral head.)

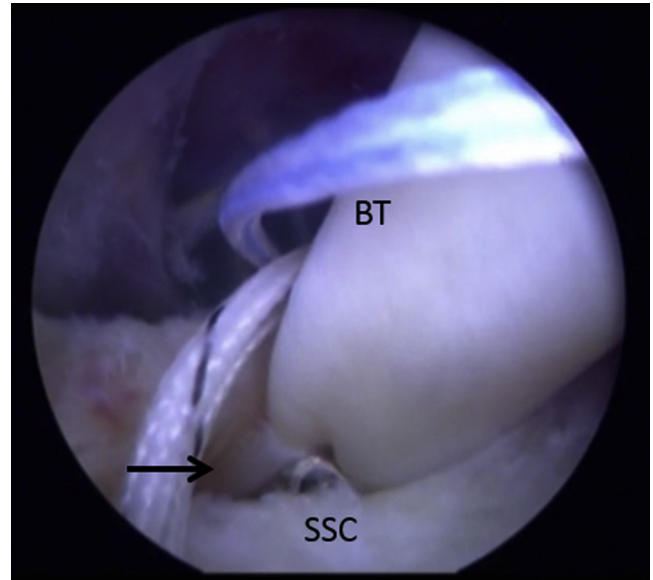


Fig 5. Arthroscopic view of the left shoulder, with the patient in the beach-chair position and the 30° arthroscope in the posterior viewing portal, showing the retrograde suture passer (arrow) piercing the biceps tendon (BT) and subscapularis tendon (SSC) simultaneously before retrieval of the suture limb.

tendon, in its subluxated position, remains positioned within the substance of the subscapularis tendon and can often effectively undergo tenodesis by simple incorporation of the biceps into the subscapularis repair through simultaneous suture passage through both tendinous structures. Likewise, regardless of whether the biceps tendon is medialized, this same technique for suture passage and tenodesis can be effectively used.

Anchor Placement and Suture Management

After placement of a Smith & Nephew 5.5-mm double-loaded HeliCoil anchor into the abraded lesser tuberosity, a 60° retrograde suture passer (DePuy Synthes, West Chester, PA) is used. Then, the first of multiple sutures is retrieved after passage through the subscapularis and biceps tendon (Fig 5). Subsequent sutures are retrieved as necessary and as dictated by the tear pattern. All sutures are tied with a sliding knot followed by 3 additional alternating half-hitches. After completion of suture tying, arthroscopic scissors are used to amputate the biceps tendon proximally, with any residual biceps tendon located proximal to the tenodesis site being excised (Fig 4). The 30° arthroscope is then switched to the anterior portal for further evaluation of the completed subscapularis repair and biceps tenodesis (Figs 6 and 7). After the repair is completed, the arm is taken through a range of motion to evaluate and confirm stability of the repair. Attention is then turned to the subacromial space for diagnostic assessment and therapeutic intervention as necessary.

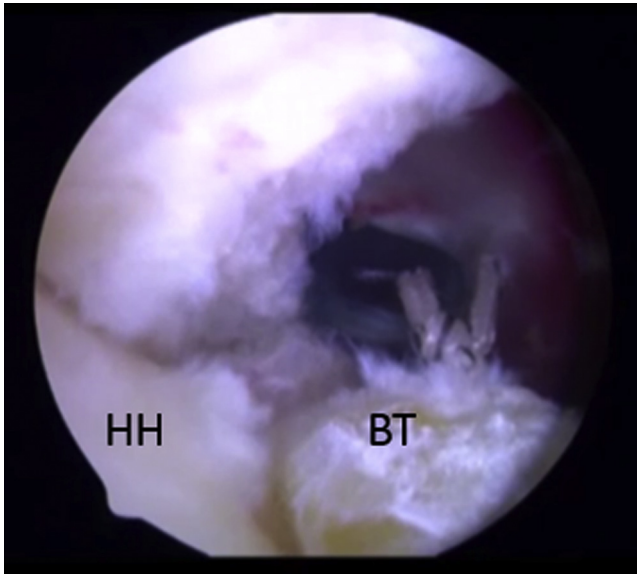


Fig 6. Arthroscopic view of the left shoulder, with the patient in the beach-chair position and the 30° arthroscope in the posterior viewing portal, showing the completed subscapularis tendon repair and biceps tenodesis. One should note that the biceps tendon (BT) that was present proximal to the tenodesis site has been excised from its labral insertion. (HH, humeral head.)

Postoperative Management

Patients are placed into a sling with a removable abduction pillow and instructed to remain immobilized for 4 weeks except for hygiene and for coordinated physical therapy including approved home exercises.

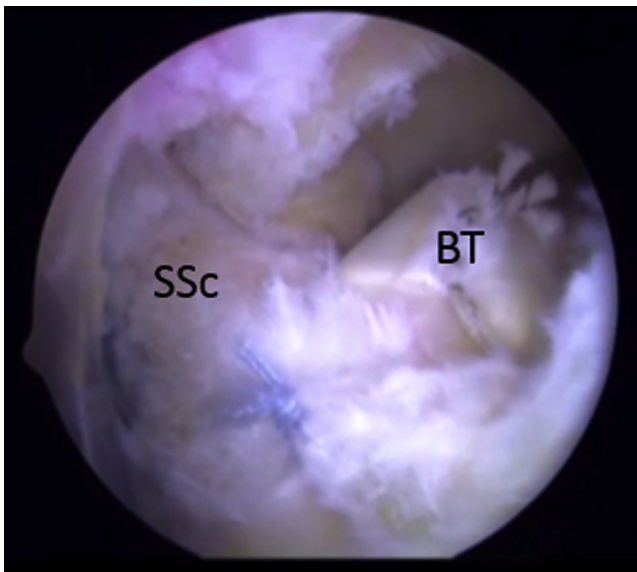


Fig 7. Arthroscopic view of the left shoulder, with the patient in the beach-chair position and the 30° arthroscope in the anterior portal, showing the completed combined subscapularis tendon (SSc) repair and biceps tenodesis. (BT, biceps tendon.)

Table 1. Advantages and Disadvantages

Advantages	
Provides secure bony biceps tenodesis	
Allows repair of subscapularis and securing of biceps tenodesis simultaneously	
Saves time in operating room because procedure is efficient	
Offers economical solution for 2 problems	
Uses standard anterior and posterior portals	
Uses 30° arthroscope	
Can be easily performed in beach-chair or lateral decubitus position	
Disadvantages	
Has learning curve for retrograde suture passer	

Physical therapy is generally initiated at 1 week postoperatively with pendulum exercises and other guided passive range-of-motion exercises started. Progressive strengthening and functional exercises are typically delayed until 4 to 6 weeks postoperatively. Between 6 and 8 weeks, full range of motion has typically been restored, and at this time, patients begin dynamic shoulder stability exercises, along with continuing shoulder strengthening and functional activity restoration exercises. Shoulder strengthening is progressively increased as long as patients remain pain free during this period. During weeks 13 to 20, rehabilitation includes more aggressive shoulder strengthening exercises that are progressed more rapidly and a focus on functional and sports-specific exercises. At 20 weeks, patients are gradually allowed to return to sports and all other activities as tolerated.

Discussion

A common association between biceps tendon pathology and subscapularis tears has been previously recognized by a number of authors. Koo and Burkhart¹⁵ showed that the insertional footprint of the biceps

Table 2. Pearls, Pitfalls, Risks, and Limitations

Pearls	
Have an assistant internally rotate the arm when debriding the lesser tuberosity and subscapularis tendon.	
Complete debridement of the rotator interval for visualization.	
Use a retrograde suture passer.	
Secure the biceps tendon before cutting the biceps tendon from the insertion on the labrum.	
Pitfalls	
Failure to recognize subluxation of biceps tendon	
Failure to recognize upper-border subscapularis tear	
Incomplete debridement of rotator interval	
Failure to capture both biceps and subscapularis tendons with passing of suture retrieval device	
Risks	
Incomplete debridement of the lesser tuberosity and subscapularis tendon can provide poor visualization, resulting in medialization of the subscapularis footprint.	
Limitations	
One anchor could be insufficient for larger tears of the subscapularis if simultaneously performing biceps tenodesis.	

tendon is immediately adjacent to the upper subscapularis tendon attachment to the lesser tuberosity. Tears at the upper subscapularis are usually accompanied by disruption of the medial biceps sling, often causing biceps subluxation.¹⁵ Urita et al.¹⁶ recently showed that patients with preoperative magnetic resonance imaging showing subscapularis tears were over 6 times more likely to have a severe grade of proximal biceps tendon disorder identified intraoperatively than patients without a subscapularis tear. Recently, Katthagen et al.¹⁷ achieved excellent results with the use of arthroscopic single-anchor repair of upper-third subscapularis tears along with open subpectoral biceps tenodesis.

The surgical technique presented in this article illustrates an effective and efficient technique for combined biceps tenodesis and subscapularis repair. Through experience involving many such combined cases of biceps tendon tenodesis and subscapularis repair, we have found that this combined technique provides reliable, reproducible, and secure fixation for both pathologic entities. One advantage of this technique is its relative simplicity compared with other techniques for biceps tenodesis that obligate the surgeon to perform either an arthroscopic or open tenodesis in a site that is remote and separate from the subscapularis repair site. In addition, by using a single suture anchor to repair the subscapularis and also accomplish biceps tenodesis, significant cost savings are potentially realized. This technique, however, may have less utility in cases in which the proximal biceps is so diseased that suture fixation cannot achieve adequate tenodesis site security and a more distal location on the humerus for tenodesis may be more appropriate. Table 1 lists advantages and disadvantages of the procedure, and Table 2 shows pearls and pitfalls. Although larger or more medialized subscapularis tears may require more suture anchors than the illustrated case, this repair technique that incorporates the biceps into the subscapularis repair can often still be carried out nonetheless.

References

1. Barber FA, Field LD, Ryu RK. Biceps tendon and superior labrum injuries: Decision making. *Instr Course Lect* 2008;57:527-538.
2. Bennett WF. Specificity of the Speed's test: Arthroscopic technique for evaluating the biceps tendon at the level of the bicipital groove. *Arthroscopy* 1998;14:789-796.
3. Gill HS, El Rassi G, Bahk MS, Castillo RC, McFarland EG. Physical examination for partial tears of the biceps tendon. *Am J Sports Med* 2007;35:1334-1340.
4. Sakurai G, Ozaki J, Tomita Y, Kondo T, Tamai S. Incomplete tears of the subscapularis tendon association with tears of the supraspinatus tendon: Cadaveric and clinical studies. *J Shoulder Elbow Surg* 1998;7:510-515.
5. Nho SJ, Strauss EJ, Lenart BA, et al. Long head of the biceps tendinopathy: Diagnosis and management. *J Am Acad Orthop Surg* 2010;18:645-656.
6. Elser F, Braun S, Dewing CB, Giphart JE, Millet PJ. Anatomy, function, injuries, and treatment of the long head of the biceps brachii tendon. *Arthroscopy* 2011;27:581-592.
7. Virk MS, Nicholson GP. Complications of proximal biceps tenotomy and tenodesis. *Clin Sports Med* 2016;35:181-188.
8. Green JM, Getelman MH, Snyder SJ, Burns JP. All-arthroscopic suprapectoral versus open subpectoral tenodesis of the long head of the biceps brachii without the use of interference screws. *Arthroscopy* 2017;33:19-25.
9. Strauss EJ, Salata MJ, Kercher J, et al. The arthroscopic management of partial-thickness rotator cuff tears: A systematic review of the literature. *Arthroscopy* 2011;27:568-580.
10. Lo IK, Burkhart SS. Transtendon arthroscopic repair of the partial-thickness, articular surface tears of the rotator cuff. *Arthroscopy* 2004;20:214-220.
11. Stuart KD, Karzel RP, Ganjianpour M, Snyder SJ. Long term outcome for arthroscopic repair of partial articular sided supraspinatus tendon avulsion. *Arthroscopy* 2013;29:818-823.
12. Lyons TR, Savoie FH, Field LD. Arthroscopic repair of partial-thickness tears of the rotator cuff. *Arthroscopy* 2001;17:219-223.
13. Fukuda H. The management of partial-thickness tears of the rotator cuff. *J Bone Joint Surg Br* 2003;85:3-11.
14. Denard PJ, Burkhart SS. Arthroscopic recognition and repair of the torn subscapularis tendon. *Arthrosc Tech* 2013;2:e373-e379.
15. Koo SS, Burkhart SS. Subscapularis tendon tears: Identifying mid to distal footprint disruptions. *Arthroscopy* 2010;26:1130-1134.
16. Urita A, Funakoshi T, Amano T, et al. Predictive factors of the long head of the biceps tendon-bicipital groove morphology and subscapularis tendon tear. *J Shoulder Elbow Surg* 2016;25:384-389.
17. Katthagen JC, Vap AR, Tahal DS, Horan MP, Millet PJ. Arthroscopic repair of isolated partial- and full-thickness upper third subscapularis tendon tears: Minimum 2-year outcomes after single-anchor repair and biceps tenodesis. *Arthroscopy* 2017;33:1286-1293.